Neuroscience Letters 606 (2015) 100–105

Contents lists available at ScienceDirect

Neuroscience Letters

journal homepage: www.elsevier.com/locate/neulet

Research paper

Cerebral alterations of type 2 diabetes mellitus on MRI: A pilot study

Bo Peng[a,b,c,1], Zhiye Chen[d,1], Lin Ma[d,*], Yakang Dai[a,*]

[a] Suzhou Institute of Biomedical Engineering and Technology, Chinese Academy of Sciences, Suzhou 215163, China
[b] University of Chinese Academy of Sciences, Beijing 100049, China
[c] Changchun Institute of Optics, Fine Mechanics and Physics, Chinese Academy of Sciences, Changchun 130033, China
[d] Department of Radiology, PLA General Hospital, Beijing 100853, China

HIGHLIGHTS

- Declines of gray matter volume, cortical thickness, and surface area were found in T2DM.
- The findings indicated that T2DM probably caused brain changes in specific regions.
- The potential neural alterations of T2DM may help early diagnose the disease.

ARTICLE INFO

Article history:
Received 3 July 2015
Received in revised form 18 August 2015
Accepted 18 August 2015
Available online 22 August 2015

Key words:
Type 2 diabetes mellitus
Brain MRI
Gray matter volume
Cortical thickness
Surface area

ABSTRACT

This study is to investigate gray matter volume, cortical thickness, and surface area of the brain in patients with type 2 diabetes mellitus (T2DM). High resolution T1-weighted MR images were obtained from eighteen T2DM and seventeen normal controls. All images were processed using our newly developed BrainLab toolbox. Declines of gray matter volume, cortical thickness, and surface area were found in T2DM patients. Significantly reduced ROIs of gray matter volume happened in subcortical gray nuclei (left caudate and right caudate), and significantly reduced ROIs of cortical thickness occurred in temporal lobe (left superior temporal gyrus), parietal lobe (left angular gyrus), and occipital lobe (right superior occipital gyrus, left middle occipital gyrus and right cuneus). Apparently reduced ROIs of surface area were mainly distributed in frontal lobe (right superior frontal gyrus (dorsal) and left paracentral lobule). The findings indicated that T2DM caused brain changes in specific regions. This work revealed neural alterations of T2DM, which had a great significance in early diagnosis of the disease.

1. Introduction

Examination of brain changes from brain magnetic resonance (MR) imaging is critical in type 2 diabetes mellitus (T2DM) diagnosis. T2DM is a common metabolic disorder that characterizes by a slowing mental speed and a diminished mental flexibility in an aging population. Cross-sectional study of several population-based articles reveals that diabetes would not only accelerate the cognitive decline but also increase the incidence of dementia [1]. A longitudinal investigation demonstrates that T2DM moderates decrements in information-processing speed during a 4-year follow-up study [2]. Insulin resistance and blood glucose level have an effect on cognitive impairment (CI) in T2DM. In addition, decreased insulin receptor expression in brain, impaired insulin signaling, and reduced insulin levels in cerebrospinal fluid (CSF) are associated with CI [3]. Though diabetes may cause hippocampal amnestic type mild cognitive impairment via both vascular and neurodegenerative processes, it could not be excluded that neurodegenerative cognitive profile is caused by hippocampal atrophy in a pure vascular process [4]. These studies demonstrate that brain structure alterations in T2DM may affect the cognitive function.

Neuroimaging plays an important role in exploring the diabetic brain changes, and MR is a safe and effective method. Thus, brain MR images are widely used to reveal brain abnormalities in neuroscience. Studies of brain MR images in patients with T2DM have appeared over the past years. Volumetric studies focused on structural abnormalities indicate that global brain atrophies and microstructural lesions occur in cerebral gray matter (GM) and white matter (WM), which affects structural and functional connectivity [5]. Slightly more global brain atrophies between T2DM and normal controls (NC) increase gradually over time [6]. According to a T2DM-related study, GM losses are distributed mainly in medial temporal, anterior cingulate, and medial frontal lobes,

* Corresponding author.
E-mail addresses: cjr.malin@vip.163.com (L. Ma), daiyk@sibet.ac.cn (Y. Dai).
[1] These authors contributed equally to this work.

http://dx.doi.org/10.1016/j.neulet.2015.08.030
0304-3940/

while WM losses are distributed in frontal and temporal regions [7]. Significant volumetric reductions in hippocampus, amygdala, prefrontal cortex, anterior cingulate, and basal ganglia have been shown among those with depressed mood symptoms [8]. Patients with T2DM present reduced GM densities and decreased cerebral glucose metabolism in several fronto-temporal brain regions after controlling for various vascular risk factors [9]. Women with T2DM have smaller total brain volumes and smaller GM volume but not WM volumes, both overall and within the major lobes [10]. As to cortical thickness, previous studies of cortical GM thicknesses have emphasized that left anterior cingulate region decreases in T2DM subjects [11]. Regional cortical thinning is demonstrated in middle temporal gyrus, posterior cingulate gyrus, precuneus, right lateral occipital gyrus and entorhinal cortex bilaterally for patients with T2DM compared with NC [12]. Quite a few studies have analyzed the brain surface in detail. According to a cerebral cortical study, the total cortical surfaces for both hemispheres are consistently lower in the T2DM group, especially in the right hemisphere. And post-hoc regional analyses have revealed significant differences in hippocampal region and middle temporal gyrus [13].

The neuron cells (which constitute of GM) with the same function get together to form the nerve center and adjust a specific physiological function. The major function of GM is processing information. Cortex is regarded as the highest achievement of biological evolution and the foundation of the ability of human thinking [14]. Obvious alterations of cortex happen with the development, aging, and disease of the brain, which reflects the state of the brain tissue and the level of the disease related to neurodegeneration [15]. However, separated analyses of volume, cortical thickness, and surface area cannot completely reveal the integrated alterations of T2DM. The advantage of combining the three characters together is to discover more detailed abnormalities of the brain. To address the need for analysis of volumetric and cortical alterations in T2DM from brain MR images, a toolbox called BrainLab is utilized to process the brain MR images for detection of subtle structural changes in the brain.

2. Methods

2.1. Participants

Eighteen T2DM (aged 44–83, mean age 61.2 years) and seventeen NC (aged 78–76, mean age 62.2 years) were recruited for this study. T2DM was diagnosed by at least one of the inclusion criteria described in [16]: a fasting plasma glucose (FPG) level >7.0 mmol/L, a 2 h plasma glucose level >11.1 mmol/L during an oral glucose tolerance test, or a prior diagnosis of T2DM. The initial exclusion criteria included the following: any prior insulin therapy, a history of dementia, cardiovascular complications (definite cerebral infarction or encephalomalacia), cranial trauma, central nervous system inflammatory disease, use of psychoactive drugs or hormones, dehydration, or overhydration. The same exclusion criteria were applied to NC, and none of NC had a history of hypertension. All of the participants were right-handed and underwent a Mini Mental State Examination (MMSE) [17] for the purpose of excluding dementia. Written informed consent was obtained from all participants according to the approval of the ethics committee of the local Institutional Review Board.

2.2. MR imaging

All MR images were acquired on a 3.0 Tesla MR system (SIGNA EXCITE, GE Healthcare, Milwaukee, WI, USA), and a conventional eight-channel phased array head coil was also used. A high resolution three-dimensional T1-weighted fast spoiled gradient recalled echo sequence generating 118 contiguous axial slices (repetition time [TR] = 6.3 ms, echo time [TE] = 2.8 ms, flip angle = 15, field of view [FOV] = 24 cm × 24 cm, matrix = 256 × 256, in-plane resolution of 0.9375 mm × 0.9375 mm, number of acquisitions [NEX] = 1) was used. Fast fluid-attenuated inversion recovery images (TR = 8802 ms, TE = 124.3 ms, inversion time = 2200 ms, slice thickness = 4 mm, gap = 1 mm, matrix = 256 × 256, FOV = 24 cm × 24 cm, NEX = 1) were obtained for general assessment purposes. The scan protocol was identical for all participants.

2.3. Image processing

All structural brain MR images were processed using BrainLab [18], running under Linux platform. The main functional modules consisted of image preprocessing, brain extraction, tissue segmentation, brain labeling, cortical surface reconstruction, and ROI analysis. All these steps were executed automatically: (1) original brain MR images were normalized in orientations, voxel sizes, and volume sizes obeying the right-hand rule. N3 bias field correction was to remove the intensity inhomogeneity. (2) 3D deformable-surface-based brain extraction algorithm [19] removed non-brain tissue from the preprocessed images. (3) Level-sets-based tissue segmentation algorithm [20] separated WM, GM, CSF, and background by constraining the cortical thickness within a biologically reasonable range. (4) Map of pre-labeled ROIs were mapped onto the T2DM subjects [21]. (5) Accurate reconstruction of inner, central, and outer cortical surfaces was achieved by a deformable surface method [22]. Specifically, the inner surface was reconstructed by topology correction of WM volume and tessellating the corrected WM volume as a triangular mesh, and then central and outer surfaces were deformed by forced derived Laplace equations. (6) ROI volumes and cortical thicknesses were measured respectively according to the number of voxels. All the image processing algorithms implemented in BrainLab were already published in leading journals and showed improved accuracy and effectiveness compared with similar algorithms, which made our structural analysis results credible.

We obtained 90 volumetric ROIs [23] and 78 cortical ROIs (ignoring 12 subcortical regions) [24]. Considering individual differences in brain volume, the numerical volumes of gray matter on each ROI were adjusted to the normalized volume by dividing the total brain volume.

2.4. Statistical analysis

The continuous variables were described in mean and standard deviation (SD). An independent sample *t*-test ($p < 0.05$) was applied to compare the quantitative data, such as age and weight. A *Chi-square* test ($p < 0.05$) was used to compare gender between groups. In comparison of GM volume, cortical thickness, and surface area, the significance level was set to be 0.1 to conduct a pilot study, which indicated potential trends at least. Multiple correction was not performed since studies focus on potential trends of structural abnormalities. The statistical analysis was performed using STATA 13.0 (StataCorp, College Station, Texas, USA).

3. Results

Age and weight distribution showed no significant difference between T2DM and NC (Table 1). Volumetric and cortical differences could be detected compared with the two groups in Fig. 1. The GM volume, cortical thickness, and surface area encoded by the color from blue (smaller, thinner) to red (larger, thicker). Mean values and SD values of GM volume, cortical thickness, surface area,

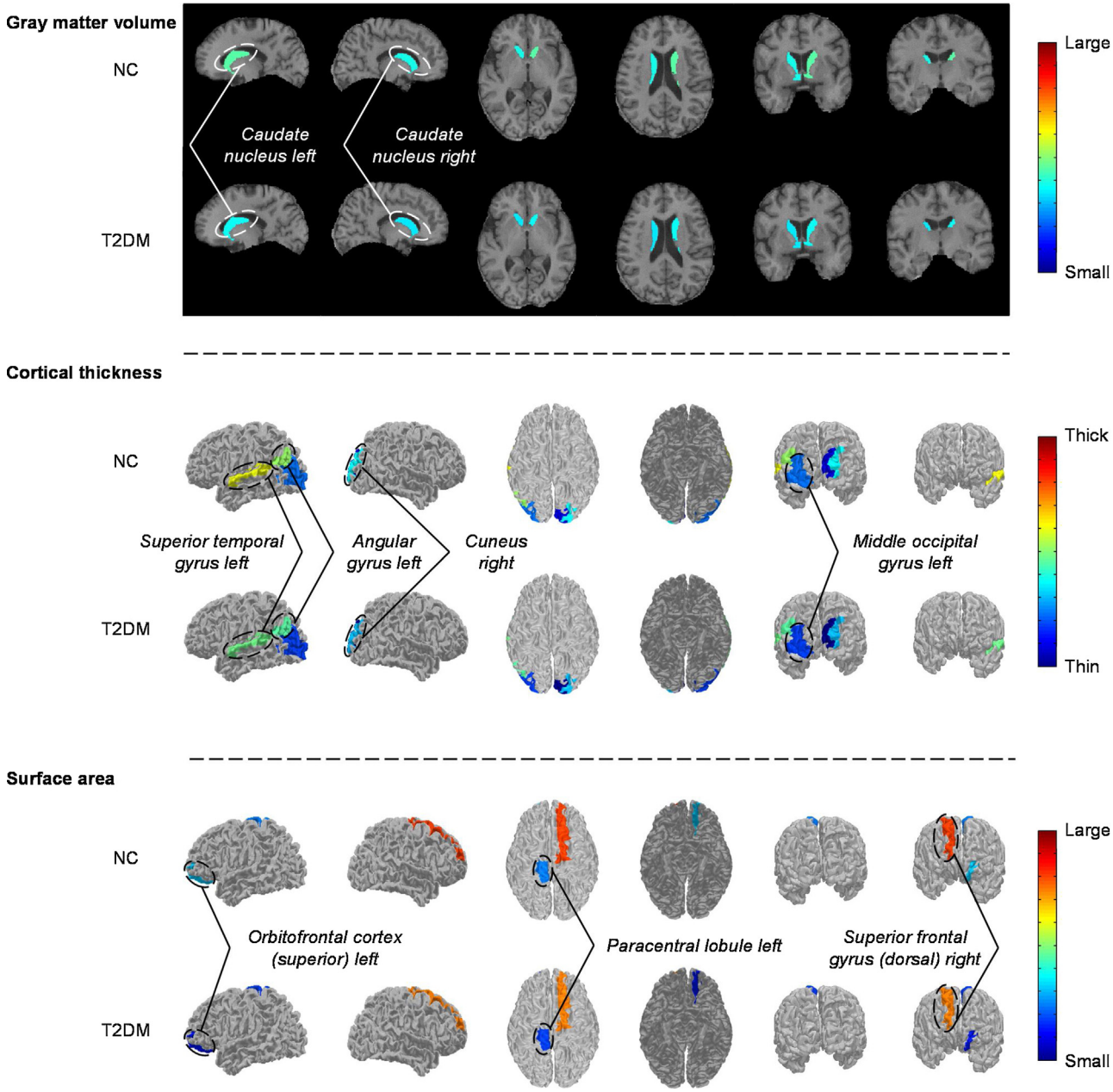

Fig. 1. The ROIs with statistical significant decline on volume, cortical thickness, and surface area were shown. The gray matter volume, cortical thickness, and surface area were encoded by the color from blue (small, thin) to red (large, thick). (For interpretation of the references to color in this figure legend, the reader is referred to the web version of this article.)

Table 1
Subject characteristics. There were no significant differences between the two groups in gender, age, and weight.

	NC $n=17$	T2DM $n=18$	Statistics	p Values
Gender	N(%)	N(%)	Chi-sq = 0.05	0.8259
Male	6(35)	7(39)		
Female	11(65)	11(61)		
	Mean(SD)	Mean(SD)		p Values
Age	61.29(10.05)	62.11(7.46)	$t=0.31$	0.94
Weight	71.18(8.56)	71.39(8.36)	$t=0.07$	0.78

*$p<0.05$.
The methods of statistical analysis for quantitative data are t-test (t value), and chi-square (chi-sq values) test for qualitative data.

as well as the difference values and the p values of each group, are provided in Table 2.

3.1. GM volume

Significant group differences between T2DM and NC on GM volume are in left caudate ($p=0.0833$) and right caudate ($p=0.0542$). According to the difference value in Table 2, the GM volumes of left caudate and right caudate decrease significantly compared with controls. Scatter plots of the mean GM volume in these ROIs are shown in Fig. 2.

3.2. Cortical thickness

Significant thickness decline in left superior temporal gyrus ($p=0.0631$), left angular gyrus ($p=0.0558$), left middle occipital

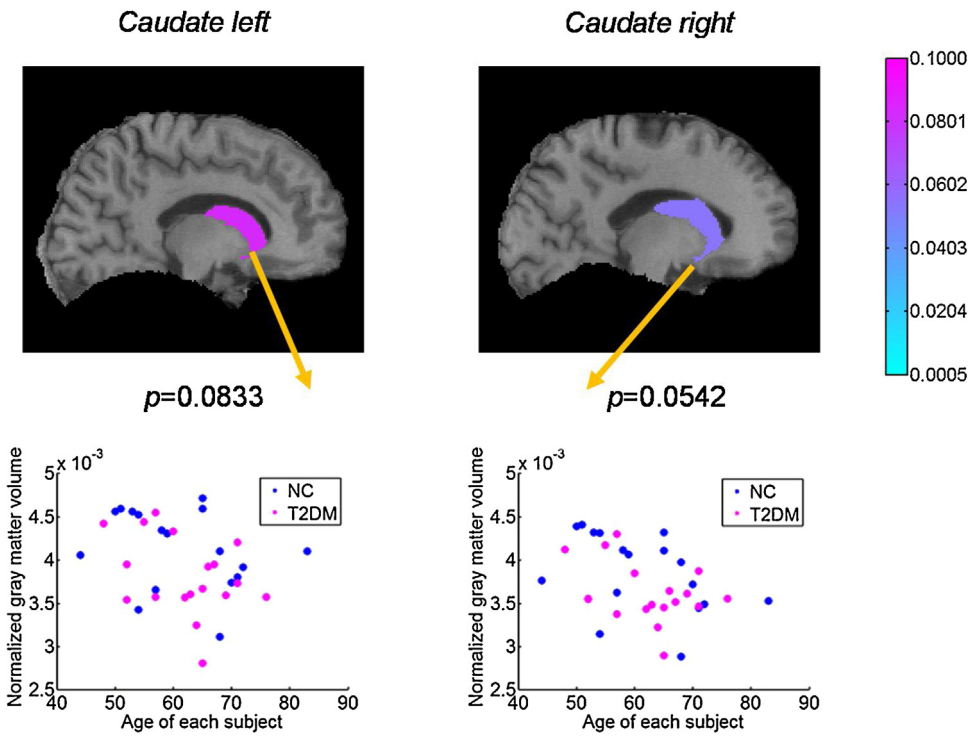

Fig. 2. Results of the *p* values and the scatterplots of regional mean gray matter volume for NC and T2DM are shown. The color bar of *p* value is provided on the right. Gray colors on the brain indicate non-significant regions.

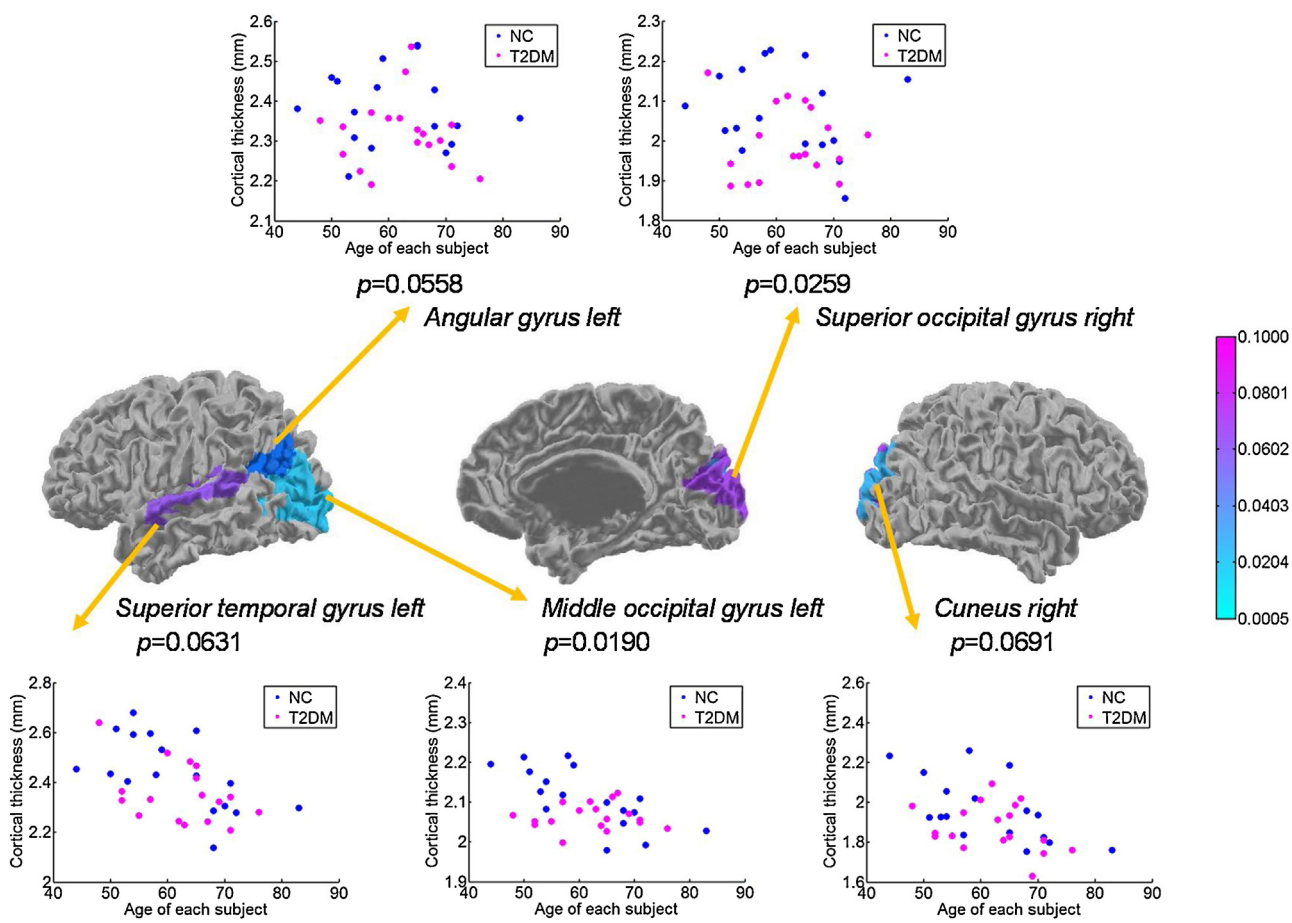

Fig. 3. Results of the *p* values and the scatterplots of cortical thickness for NC and T2DM are shown. The color bar of *p* value is provided on the right. Gray colors on the brain indicate non-significant regions.

Table 2
Gray matter volume, cortical thickness, and surface area of the statistical significant ROIs were listed below.

ROI	NC Mean(SD)	T2DM Mean(SD)	Difference	*p* Values
Gray matter volume				
Caudate left	0.0039(0.0005)	0.0038(0.0003)	-0.0001	0.0833
Caudate right	0.0041(0.0005)	0.0040(0.0005)	-0.0001	0.0542
Cortical thickness				
Superior temporal gyrus left	2.4393(0.1490)	2.3535(0.1135)	−0.0858	0.0631
Angular gyrus left	2.3827(0.0969)	2.3212(0.0868)	−0.0616	0.0558
Superior occipital gyrus right	2.0735(0.1085)	1.9960(0.0878)	−0.0776	0.0259
Middle occipital gyrus left	2.1105(0.0740)	2.0634(0.0320)	−0.0471	0.019
Cuneus right	1.9645(0.1625)	1.8746(0.1185)	−0.0899	0.0691
Surface area				
Superior frontal gyrus (dorsal) right	3561.8654(547.0624)	3209.4689(454.6699)	−352.397	0.0456
Paracentral lobule left	1350.8247(187.0068)	1188.6739(193.7319)	−162.151	0.0169
Orbitofrontal cortex (superior) left	1106.5250(157.1917)	1018.9364(126.4667)	−87.5886	0.0776

*$p < 0.1$.

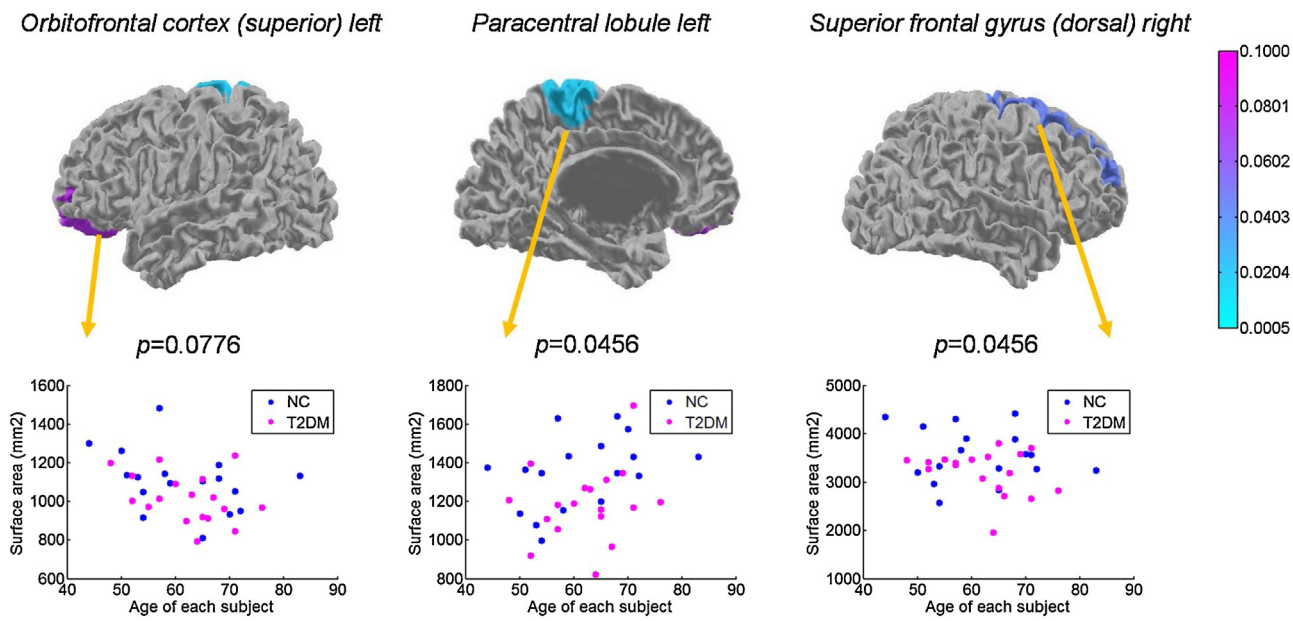

Fig. 4. Results of the *p* values and the scatterplots of surface area for NC and T2DM are shown. The color bar of *p* value is provided on the right. Gray colors on the brain indicate non-significant regions.

gyrus ($p = 0.0190$), right superior occipital gyrus ($p = 0.0259$), and right cuneus ($p = 0.0691$) compared with control group. Scatter plots of the cortical surface area in these ROIs are shown in Fig. 3.

3.3. Cortical surface area

Significantly smaller surface area are in right superior frontal gyrus (dorsal) ($p = 0.0456$), left paracentral lobule ($p = 0.0169$), and left orbitofrontal cortex (superior) ($p = 0.0776$). Further analysis reveals surface area decline in all these three ROIs compared with controls. Scatter plots of the cortical surface area in these ROIs are shown in Fig. 4.

4. Discussion

This study investigates the GM volume, cortical thickness, and surface area between T2DM and NC. Previous imaging morphometric studies of T2DM have mainly focused on the measurement of either volumetric or cortical characteristics, which is impossible to differentiate the potential abnormality among the three characteristics. With the state-of-the-art methods for brain MR image segmentation [20] and cortical surface reconstruction [22], we are able to accurately compute the characteristics of the whole brain.

Microstructural abnormalities in bilateral caudate have been found in previous studies of T2DM. Greater atrophies of WM and GM are associated with memory, executive control, and processing speed. These ROIs include the hippocampus, entorhinal cortex, posterior cingulate, dorsolateral prefrontal cortex, posterior parietal cortex, and striatum, as well as substructures of striatum: putamen, caudate nucleus, and palladium [25]. Diabetes are associated with microstructural abnormalities in frontal lobe, cerebellum, temporal lobe, right caudate, cingulate gyrus, pons, and parahippocampal gyrus [26]. Magnetization transfer ratios were significantly lower bilaterally in the head of the caudate nucleus [27]. Reduced magnetization transfer ratio shows correlations with neuropsychological task performance in the domains of learning and memory, executive function, and attention and information processing [28]. Our findings are generally consistent with the previous studies of T2DM. Caudate nucleus, located in basal ganglia, is an important part of controlling learning and memory system. Neuro cells in cerebral nuclei connect with cerebral cortex and spinal cord, controlling of voluntary movement and integrating awareness activities and motor response, and advanced cognitive functions, such as mem-

ory, emotion, and the brain's reward systems. Lesions and disorders in the basal ganglia lead to various cognitive disorders and thus tending to cause Alzheimer's disease. Alzheimer's disease group showed significant declined areas of voxels in caudate nucleus, putamen, and thalamus, as well as bilateral retrosplenial cortex [29]. Our findings concerning GM volume abnormalities in bilateral caudate may provide early warning of diabetes complications and an early signal for risk of cognitive impairment.

Reduced cortical thicknesses in our study were found with T2DM. Our findings are generally consistent with the existing findings in T2DM. Cortical atrophies are most pronounced in temporal lobe [9] and occipital regions [30] in T2DM. Increased cortical atrophies had been found in frontal, temporal, and parietal lobe [31]. Our result was consistent with the verdict that cortical thinning was associated with T2DM compared with NC [32].

Few previous studies were on cortical surface area in patients with T2DM. Significant cortical surface area differences were located in middle temporal gyrus [12]. Though not completely consistent with previous findings, ROI-based analysis revealed surface area reduction in frontal and orbital region, which reflected more subtle abnormalities sensitive to T2DM.

Each of the three characters represented specific physiological meaning. Gray matter volumes were obviously declined in T2DM, which affected the function of muscles, emotion, language, decision making, and self-control. Cortex alterations were caused by neuronal necrosis affected by hypoglycemia at the early phases of the disease. Therefore, T2DM contributed to alterations in GM volume and cortex, initiating the ability of thinking and memory problems, which made the patients more likely to get cognitive impairment.

This study had several limitations. First, as for different measurement methods for GM volume, cortical thickness, and surface area, there existed an inconsistency among the three characters since each of them reflected the specific function from different aspects. Second, the sample number of subjects was not large enough to well perform statistical analysis. But as a pilot study, our findings revealed some potential ROIs that changed the most in T2DM. This study provided a trend in brain structure alteration in T2DM.

5. Conclusion

T2DM has a detrimental effect on brain, which causes the structural abnormalities on brain. These abnormalities occur before cognitive decline develops. It has been demonstrated that the abnormalities caused by T2DM are similar to those caused by Alzheimer's disease [33]. Although MR images have been used to detect brain abnormalities, few investigations provide integrated information about volumes, cortex, and ROIs. The detection and analysis of the volumes, cortical thickness, and surface area on brain MR images reveal the T2DM alterations, which has a great significance in early diagnosis of the disease.

Acknowledgments

This work was supported in part by the Hundred Talents Program of CAS, NSFC grants (61301042, 61201117, 81171319), NSFJ grant (BK2012189), NFCPLAGH grant (13KMM41), and SSTP program (ZXY201426).

References

[1] K.V. Allen, B.M. Frier, M.W.J. Strachan, The relationship between type 2 diabetes and cognitive dysfunction: longitudinal studies and their methodological limitations, Eur. J. Pharmacol. 490 (2014) 169–175.
[2] E.V.D. Berg, Y.D. Reijmer, J.D. Bresser, et al., A 4 year follow-up study of cognitive functioning in patients with type 2 diabetes mellitus, Diabetologia 53 (2010) 58–65.
[3] R. Belfort-DeAguiar, R.T. Constable, R.S. Sherwin, M.R.I. Functional, signal fluctuations: a preclinical biomarker for cognitive impairment in type 2 diabetes, Diabetes 63 (2014) 396–398.
[4] S. Mehrabian, M. Raycheva, A. Gateva, et al., Cognitive dysfunction profile and arterial stiffness in type 2 diabetes, Diabetes 63 (2014) 2244–2252.
[5] G.J. Biessels, Y.D. Reijmer, Brain changes underlying cognitive dysfunction in diabetes: what can we learn from MRI? Diabetes 63 (2014) 2244–2252.
[6] M. Brundel, L.J. Kappelle, G.J. Biessels, Brain imaging in type 2 diabetes, Eur. Neuropsychopharmacol. 24 (2014) 1967–1981.
[7] C. Moran, T.G. Phan, J. Chen, et al., Brain atrophy in type 2 diabetes regional distribution and influence on cognition, Diabetes Care 36 (2013) 4036–4042.
[8] T. Doyle, A. Halaris, M. Rao, Shared neurobiological pathways between type 2 diabetes and depressive symptoms: a review of morphological and neurocognitive findings, Curr. Diabetes Rep. 14 (2014) 1–12.
[9] N. Garcia-Casares, M.L. Berthier, R.E. Jorge, et al., Structural and functional brain changes in middle-aged type 2 diabetic patients: a cross-sectional study, J. Alzheimer's Dis. 40 (2014) 375–386.
[10] M.A. Espeland, R.N. Bryan, J.S. Goveas, et al., Influence of type 2 diabetes on brain volumes and changes in brain volumes results from the women's health initiative magnetic resonance imaging studies, Diabetes Care 36 (2013) 90–97.
[11] O. Ajilore, K. Narr, J. Rosenthal, et al., Regional cortical gray matter thickness differences associated with type 2 diabetes and major depression, Psychiatry Res.: Neuroimag. 184 (2010) 63–70.
[12] Z. Chen, J. Sun, Y. Yang, et al., Cortical thinning in type 2 diabetes mellitus and recovering effects of insulin therapy, J. Clin. Neurosci. 22 (2015) 275–279.
[13] M. Brundel, M. van den Heuvel, J. de Bresser, et al., Cerebral cortical thickness in patients with type 2 diabetes, J. Neurol. Sci. 299 (2010) 126–130.
[14] J.L.R. Rubenstein, P. Rakic, Genetic control of cortical development, Cereb. Cortex 9 (1999) 521–523.
[15] J. Lerch, In-vivo analysis of cortical thickness using magnetic resonance images, in: PhD Thesis, Department of Neurology and Neurosurgery, McGill University, Montreal, Canada, 2005.
[16] American Diabetes Association, Diagnosis and classification of diabetes mellitus, Diabetes Care 36 (2013) S67–S74.
[17] M. Galea, M. Woodward, Mini-mental state examination (MMSE), Aust. J. Physiother. 51 (2005) 198.
[18] B. Peng, G. Li, C. Zhie, et al., Detection and analysis of T2DM Biomarkers from brain MR images using BrainLab, Proceedings of The 2014 7th International Conference on BioMedical Engineering and Informatics-BMEI (2014) 143–147.
[19] Y. Wang, J. Nie, P.T. Yap, et al., Knowledge-guided robust MRI brain extraction for diverse large-scale neuroimaging studies on humans and non-human primates, PLoS One 9 (2014) e77810.
[20] L. Wang, F. Shi, G. Li, D. Shen, 4D Segmentation of brain MR images with constrained cortical thickness variation, PLoS One 8 (2013) e64207.
[21] G. Wu, M. Kim, Q. Wang, D. Shen, Hierarchical attribute-guided symmetric diffeomorphic registration for MR brain images Medical Image Computing and Computer-Assisted Intervention—MICCA 2012, vol. 2012, Springer, Berlin Heidelberg, 2012, pp. 90–97.
[22] G. Li, J. Nie, G. Wu, Y. Wang, D. Shen, Consistent reconstruction of cortical surfaces from longitudinal brain MR images, Neuroimage 59 (2012) 3805–3820.
[23] N. Tzourio-Mazoyer, B. Landeau, D. Papathanasslou, et al., Automated anatomical labeling of activations in SPM using a macroscopic anatomical parcellation of the MNI MRI single-subject brain, Neuroimage 15 (2002) 273–289.
[24] Y. Wang, G. Li, M. Ahn, et al., Mapping longitudinal cerebral cortex development using diffusion tensor imaging. SPIE Medical Imaging, Int. Soc. Opt. Photon. 2013 (2013), 693E-86692E-7.
[25] C.M. Falvey, C. Rosano, E.M. Simonsick, et al., Macro-and microstructural magnetic resonance imaging indices associated with diabetes among community-dwelling older adults, Diabetes Care 36 (2013) 677–682.
[26] J.L. Hsu, Y.L. Chen, J.G. Leu, et al., Microstructural white matter abnormalities in type 2 diabetes mellitus: a diffusion tensor imaging study, Neuroimage 59 (2012) 1098–1105.
[27] A. Kumar, R. Gupta, A. Thomas, et al., Focal subcortical biophysical abnormalities in patients diagnosed with type 2 diabetes and depression, Arch. Gen. Psychiatry 66 (2009) 324–330.
[28] S. Yang, O. Ajilore, M. Wu, et al., Impaired macromolecular protein pools in fronto-striato-thalamic circuits in type 2 diabetes revealed by magnetization transfer imaging, Diabetes 64 (2015) 183–192.
[29] L. Zeifman, W. Eddy, O. Lopez, et al., Whole brain, voxel level analysis of grey matter volume and time to incident mild cognitive impairment or Alzheimer's disease (P4. 020), Neurology 82 (2014) 4-020.
[30] E.C. Leritz, D.H. Salat, V.J. Williams, et al., Thickness of the human cerebral cortex is associated with metrics of cerebrovascular health in a normative sample of community dwelling older adults, Neuroimage 54 (2011) 2659–2671.
[31] V. Novak, P. Zhao, B. Manor, et al., Adhesion molecules, altered vasoreactivity, and brain atrophy in type 2 diabetes, Diabetes Care 34 (2011) 2438–2441.
[32] Z. Chen, J. Sun, Y. Yang, et al., Study of cortical thinning in the patients with type 2 diabetes mellitus and the recovering effect of the insuline therapy, Zhonghua Yi Xue Za Zhi 93 (2013) 1313–1317.
[33] A. Kumar, E. Haroon, C. Darwin, et al., Gray matter prefrontal changes in type 2 diabetes detected using MRI, J. Magn. Reson. Image. 27 (2008) 14–19.